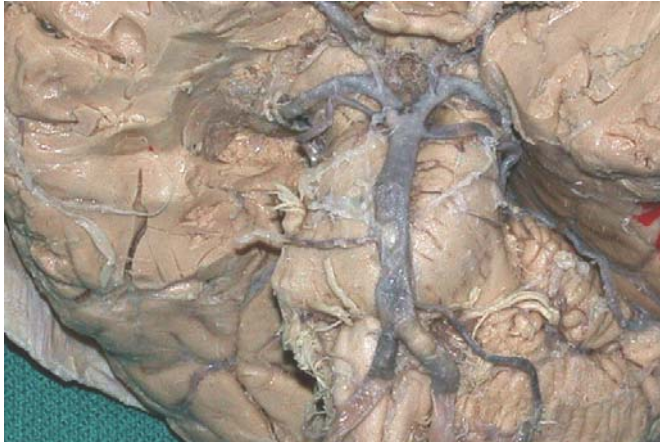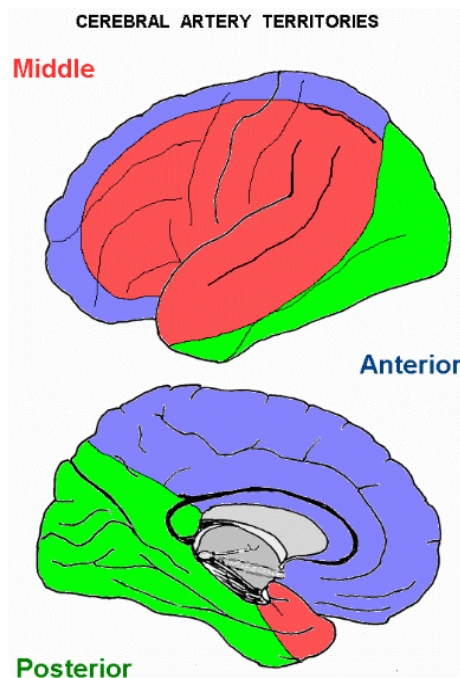


SOME LOCALIZED LESIONS AND THEIR EFFECTS



The circle of Willis can compensate for slow reduction in diameter of one (or even 3) of the major arteries to the brain.



Effects of occlusion of a cerebral artery are due to loss of function of affected cortical areas and/or subcortical white matter.

CLASSICAL OCCLUSION SYNDROMES.

Middle cerebral artery.

Occlusion of the vessel at its origin causes:

- contralateral upper-motor-neuron paralysis of the upper limb and face, with
- global aphasia if left-sided.
- Lower limb functions are spared.

- Infarction of the geniculocalcarine tract, deep to the parietal cortex, results in contralateral hemianopia.

Obstruction of branches of the MCA results in fragments of the complete syndrome, such as monoplegia, upper motor neuron facial paralysis, or receptive aphasia.

Anterior cerebral artery.

- Paralysis and sensory deficits in the contralateral lower limb and perineum.
- Urinary incontinence.

A proximal lesion - obstructing the origin of the anterior cerebral artery - causes hemiplegia affecting the limbs and lower face,

because an early branch, the recurrent artery of Heubner, supplies the internal capsule.

Proximal lesions may also cause ipsilateral anosmia from infarction of the olfactory bulb and tract.

Posterior cerebral artery.

- Infarction of the occipital lobe causes contralateral hemianopia.
- Damage to the hippocampal formation results in a memory deficit, but this soon recovers.

Bilateral posterior cerebral artery occlusions can result in a permanent inability to form new memories, in addition to blindness in both eyes.

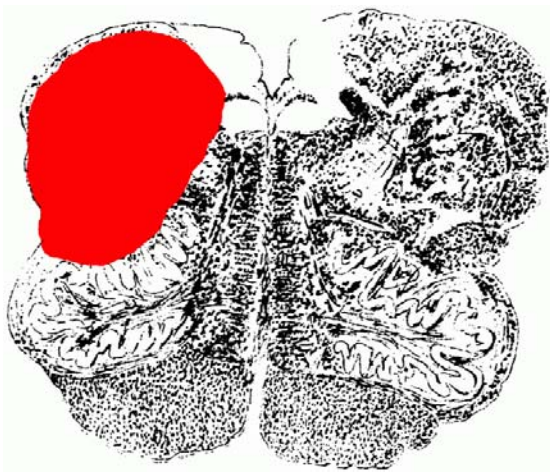
Internal carotid artery.

This vessel is frequently obstructed by atheroma, which commonly gives rise to transient symptoms of cerebral ischaemia known as transient ischaemic attacks (TIAs).

Complete, sudden obstruction cuts off most of the blood flow in the anterior and middle cerebral arteries.

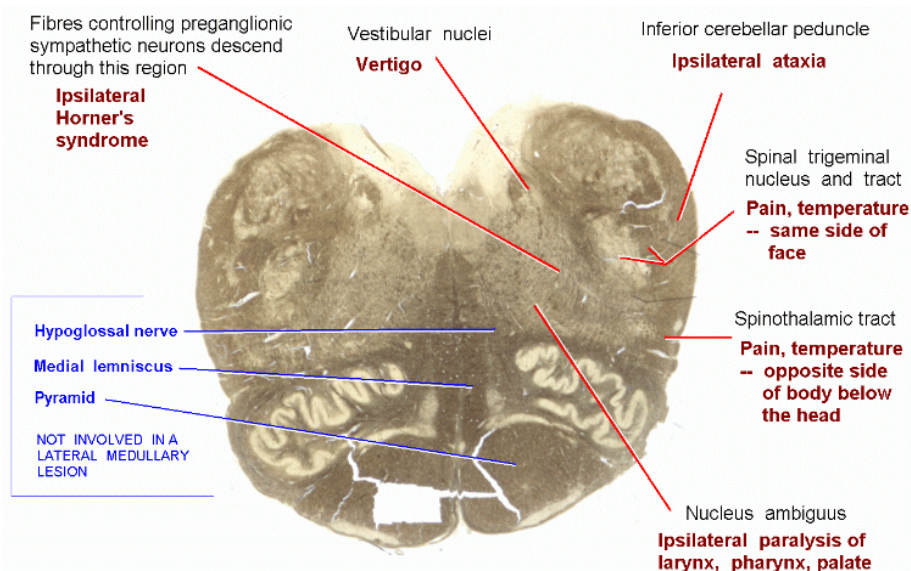
Contralateral hemiplegia with sensory deficits. If on the left side (in 90% of people), severe aphasia.

There may also be blindness in the ipsilateral eye (ophthalmic artery) with loss of the temporal visual field of the contralateral eye (anterior choroidal artery supplies optic tract).



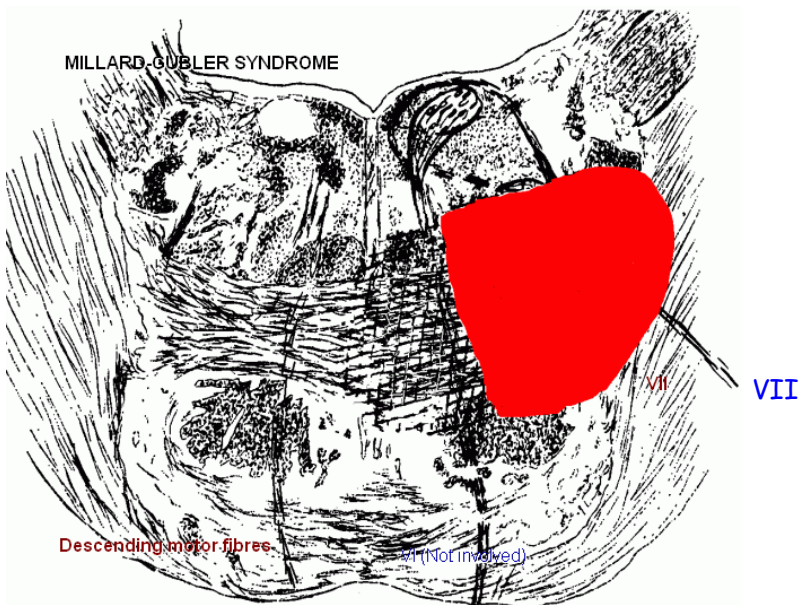
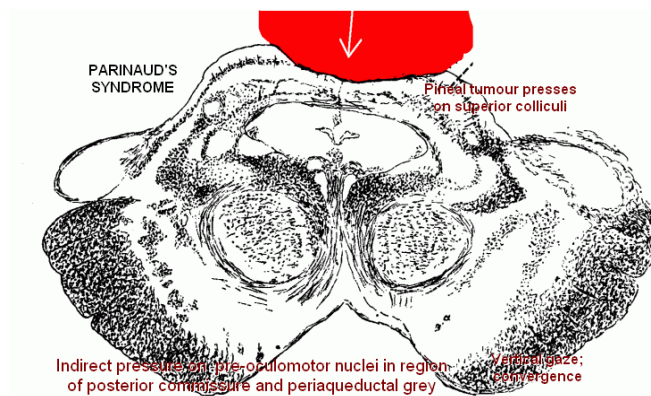
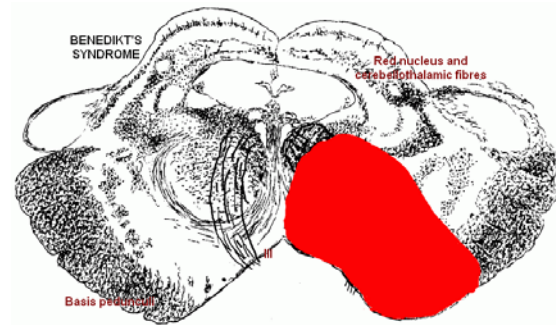
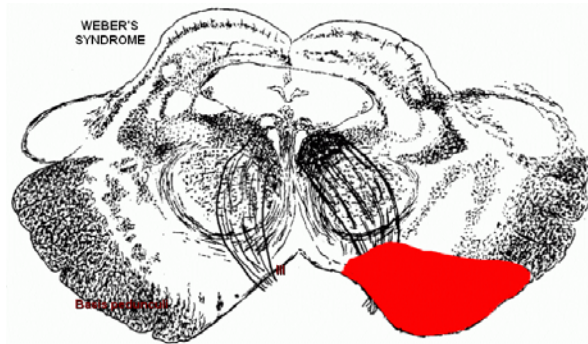
Wallenberg's syndrome. (Exact size and position of lesion is variable.)

Typically due to occlusion of a medullary branch of the posterior inferior cerebellar artery.

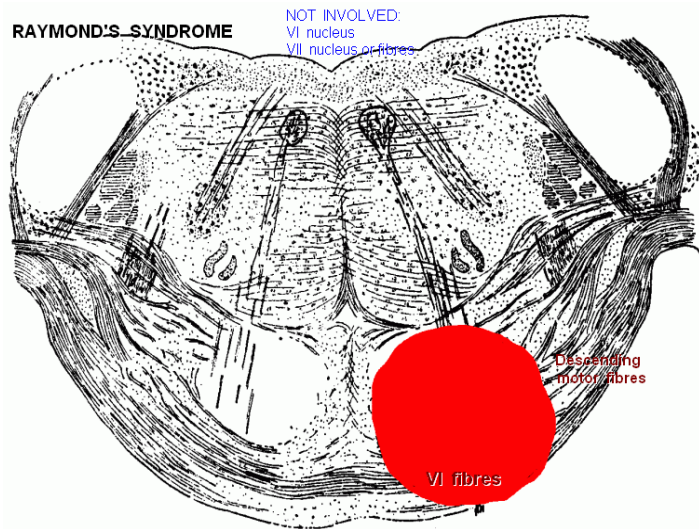


(There is a tear in the ventral part of the section; this is an artifact of preparation, not a lesion.)

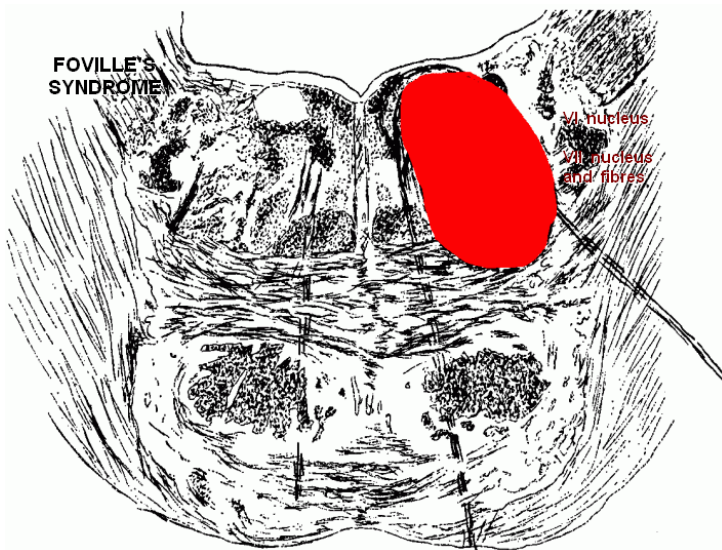
OTHER BRAIN STEM SYNDROMES. Do not attempt to memorize these.



RAYMOND'S SYNDROME



FOVILLE'S SYNDROME



DIAGNOSTIC PROBLEM.

History

Comments

Deafness, Left ear. Developed gradually; complete in 6 months.

Testing indicates central (cochlea or VIII nerve), not conduction deafness

Facial weakness, L. side, first noticed when nearly completely deaf. Increased and was a full facial paralysis in one year.

From 5 metres it is obvious that this is a lower motor neuron palsy.

During the next year :

Headache, becoming continuous.

Weakness of R. arm and leg.

On examination :

Sensory deficit on L. side of face, most marked for pain & temperature.

Uvula deviates to R. when saying "AAAH"

Tendon jerk reflexes more brisk on R. side.

Slow progression of symptoms suggests a slowly growing (benign) tumour.

The vestibulocochlear and facial nerves run alongside in the internal auditory meatus.

[Muscles around mouth and eye are affected.]

Continuous headache!

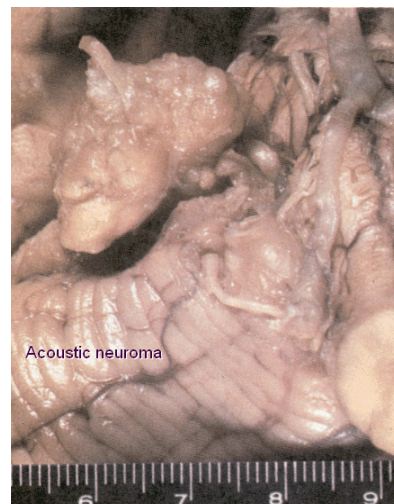
Pressure on descending motor pathways that cross the midline caudal to the level at which the tumour presses on the brain stem.

Spinal tract of V from indirect pressure. Later, V roots in subarachnoid space.

X motor palsy.

Upper motor neuron hemiparesis

Acoustic neuroma
(benign tumour that
Arises from the Schwann
cells of the vestibular
nerve and expands in the
pontocerebellar angle)



(cm)